

Oncology in Images

Massive Cutaneous Metastasis of a Renal Cell Carcinoma

Rovere R. K.¹, Lima A. S.²

¹ Oncology Unit, San Antonio Hospital, Blumeau, Santa Catarina, Brazil

² Private practice, Brusque, Santa Catarina, Brazil

We present a case of a previously healthy 60-year-old countryside woman, who has developed a swiftly growing, erythematous to violaceous lobulated mass with hyperkeratotic surface on the left forehead within the past few weeks (Fig. 1–3). A few days later, she presented with macroscopic haematuria and left flank pain. After being admitted to our oncologic unit, she was submitted to a brain, thorax and abdomen/pelvis CT scan, which revealed a huge mass on the left kidney, as well as multiple bone, lung and lymph

node metastasis. She underwent lesion biopsy which was histologically classified as clear cell carcinoma (Fig. 4), consistent with poor prognosis primary kidney cancer according to the MSKCC criteria. The patient was indicated to commence mTOR inhibitor treatment but soon she developed a rapidly progressive disease with overall health status deterioration and the treatment strategy was converted to best supportive care. The patient succumbed to the disease in less than five days after the diagnosis was established.



Rodrigo Kraft Rovere, MD
Oncology Unit
Santo Antonio Hospital
Rua Itajai 545
Blumenau, Santa Catarina
CEP 89050100 Brazil
e-mail: rodrigorovere@hotmail.com

Submitted/Obdrženo: 19. 2. 2014

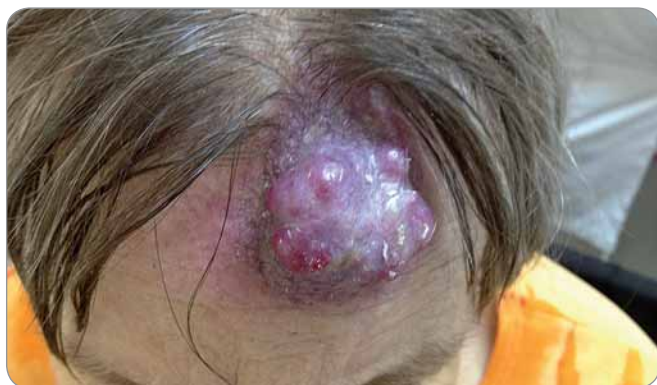

Fig. 1. Erythematous-violaceous lobulate mass on the left forehead.

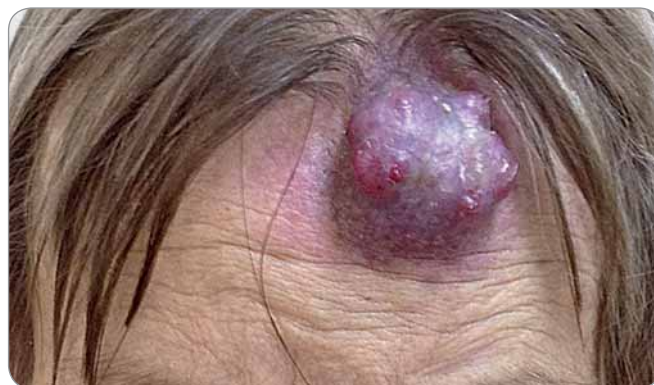

Fig. 2. Erythematous-violaceous lobulate mass on the left forehead.

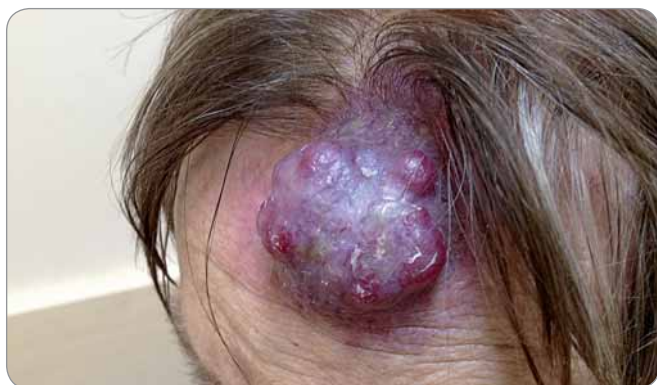

Fig. 3. Erythematous-violaceous lobulate mass on the left forehead.

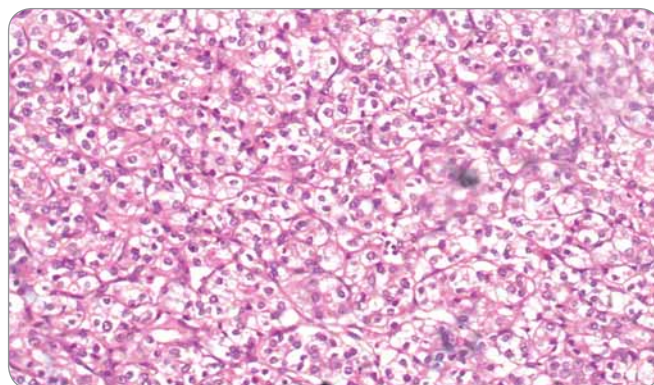


Fig. 4. Metastatic clear cell cancer.