

Bilateral Germ-Cell Testicular Cancer – Long-Term Experience

Bilaterálne germinatívne nádory testis – dlhoročné skúsenosti

Ondruš D.¹, Ondrušová M.^{2,3}, Šťastná V.⁴

¹ 1st Department of Oncology, Comenius University Faculty of Medicine, St. Elisabeth Cancer Institute, Bratislava, Slovak Republic

² St. Elisabeth University of Health and Social Sciences, Bratislava, Slovak Republic

³ Cancer Research Institute, Slovak Academy of Science, Bratislava, Slovak Republic

⁴ Department of Public Health, Faculty of Health Sciences and Social Work, Trnava University in Trnava, Slovak Republic

Summary

Background: Germ cell testicular cancer (TC) patients have an increased risk of developing a contralateral TC. This paper presents a retrospective analysis of patients with bilateral TC from a database of a single center and aims to highlight the need for an individual approach. **Material and Methods:** In the study period from January 1970 to June 2013, a total of 1,438 patients with primary TC were diagnosed. The group comprised of 1,370 patients with unilateral TC and 68 patients with bilateral TC. Bilateral TC patients were evaluated regarding the age at presentation and the histology of tumor and then compared with the group of patients with unilateral TC. **Results:** The mean age of the patients with unilateral TC was 31.7 years. This group of patients consisted of 408 patients with seminoma and 962 patients with non-seminomatous TC. The group of 68 patients with bilateral TC involved 63 patients with metachronous disease and five patients who developed TCs simultaneously. The mean age at diagnosis of primary tumor in patients with metachronous bilateral TC (25.8 years) was significantly earlier in comparison to patients with unilateral disease. Among 24 patients with seminoma there were 17 patients who subsequently developed a second malignancy of an identical histological type. In the group of 39 patients with initial non-seminomatous TC there were 15 patients with discordant histology of the second tumor. In the metachronous disease group, patients with primary seminoma were significantly older than those with initial non-seminomas. **Conclusions:** All patients with unilateral TC have an increased risk of developing a contralateral TC, years and even decades after the initial diagnosis. Management of subsequent TC should be individualized for each patient according to the histology and clinical stage of the primary tumor, as well as the therapeutic strategy applied initially. The further management should involve a long-term follow-up and life-long testosterone substitution.

Key words

bilateral testicular cancer – second primary neoplasms – seminoma – non-seminomatous germ cell tumor

The authors declare they have no potential conflicts of interest concerning drugs, products, or services used in the study.

Autoři deklarují, že v souvislosti s předmětem studie nemají žádné komerční zájmy.

The Editorial Board declares that the manuscript met the ICMJE “uniform requirements” for biomedical papers.

Redakční rada potvrzuje, že rukopis práce splnil ICMJE kritéria pro publikace zasílané do biomedicínských časopisů.



prof. Dalibor Ondrus, MD, DSc.
1st Department of Oncology
Comenius University Faculty
of Medicine
St. Elisabeth Cancer Institute
Heydukova 10
812 50 Bratislava
Slovak Republic
e-mail dalibor.ondrus@ousa.sk

Submitted/Obdrženo: 10. 7. 2013

Accepted/Přijato: 28. 7. 2013

Súhrn

Úvod: Pacienti s germinatívnym nádorom testis majú zvýšené riziko vzniku nádoru v kontralaterálnom testis. Cieľom tejto práce bolo analyzovať skupinu pacientov s bilaterálnym testikulárnym nádorom z databázy jedného centra a upozorniť na potrebu individuálneho postupu. **Materiál a metódy:** V období január 1970 až jún 2013 bolo sledovaných celkovo 1 438 pacientov s primárnym germinatívnym testikulárnym nádorom. Súbor sa delí na 1 370 pacientov s jednostranným nádorom a 68 pacientov s bilaterálnym nádorom testis. Pacienti s bilaterálnym nádorom testis boli analyzovaní podľa veku a histologického typu a porovnaní so skupinou pacientov s jednostranným ochorením. **Výsledky:** Priemerný vek 1 370 pacientov s jednostranným nádorom testis bol 31,7 rokov. V tejto skupine bolo 480 pacientov so seminómom a 962 pacientov s ne seminomatóznym nádorom testis. V skupine 68 pacientov s bilaterálnym nádorom bolo 63 pacientov s metachrónnym výskytom a päť pacientov so simultánnym výskytom nádoru. U pacientov s metachrónnym bilaterálnym výskytom sa prvý nádor zistil v signifikantne mladšom veku (v priemernom veku 25,8 rokov) v porovnaní s nádorom pri jednostrannom výskyte. V skupine 24 pacientov so seminómom v prvom nádore bolo 17 pacientov s identickým typom (seminóm) pri druhom nádore. V skupine 39 pacientov s prvým nádorom ne seminomatózneho typu bolo 15 pacientov s nálezom seminómu pri druhom nádore. Pacienti so seminómom v prvom nádore boli signifikantne starší v porovnaní s pacientmi s ne seminomatóznym typom prvého nádoru. **Záver:** Pacienti s jednostranným nádorom testis majú zvýšené riziko rozvoja nádoru v kontralaterálnom testis aj po desiatkach rokov. Manažment druhého nádoru by sa mal individualizovať pre každého pacienta podľa histologického typu, spôsobu liečby a klinického štádia prvého nádoru ako aj zmysle dlhoročného sledovania a substitúcie testosterónom.

Kľúčové slová

bilaterálny nádor testis – sekundárny primárny nádor – seminóm – ne seminomatózny germinatívny nádor

Introduction

In patients with a history of primary testicular cancer, the development of a subsequent tumor in the remaining testis is not an unknown phenomenon. The first case of bilateral testicular cancer (TC) was described by Livingstone in 1805 [1]. Hamilton and Gilbert [2] believed that a history of testicular cancer is associated with a several hundred or even several thousand-fold higher risk of developing a metachronous contralateral tumor. In medical centers all over the world, the incidence of bilateral TC varies between 1–7.8% [3]. Bilateral TCs can occur simultaneously or consecutively after a certain time interval. The incidence of bilateral TC has increased over the last decades due to long-term survival of patients receiving efficient treatment for the primary tumor [4]. One can say, that the increasing incidence of bilateral TC is thus associated with the advances in chemotherapy, particularly the success of cisplatin-based regimens [5].

This paper presents a retrospective analysis of patients with bilateral TC from a database of a single center and aims to highlight the need for an individual approach.

Material and Methods

Between January 1970 and June 2013 a total of 1,438 patients with primary germ cell testicular cancer (TC) were re-

gistered in our center. The group comprised of 1,370 (95.3%) patients with unilateral TC and 68 (4.7%) patients with bilateral TC. These patients were categorized according to the age and histological type of both tumors and contrasted to in comparison to the population of patients with unilateral TC. Continuous variables were described by means of descriptive statistics (number, mean, median, 25–75% quantile). T-test was applied for statistical analysis. Two-sided tests were employed, with the critical level set at $\alpha = 0.05$. A p-value < 0.05 was considered to be statistically significant.

Results

The average age of patients at the time of unilateral TC diagnosis was 31.7 years (median 30.3 years, 25–75% quantile was 25.4 and 36.7 years). In the group of patients with unilateral TC, there were 408 patients with pure seminoma with a mean age of 35.8 years (median 34.2 years, 25–75% quantile 29.8 and 40.8 years) and 962 patients with a nonseminomatous TC with the mean age of 29.9 years (median 28 years, 25–75% quantile 23 and 34 years). The difference is statistically significant ($p < 0.001$).

Among 68 patients with bilateral TC, 63 patients with a metachronous disease had an average age of 25.8 years at diagnosis of the first tumor (me-

dian 25.1 years, 25–75% quantile 21.4 and 29.4 years). The second malignancy occurred at a mean age of 34.2 years (median 32.5 years, 25–75% quantile was 29.6 and 39.0 years). Among patients with metachronous bilateral disease, the first TC was diagnosed at significantly earlier age in comparison to patients suffering unilateral TC ($p < 0.005$). Of the 63 patients with metachronous TC, there were 24 patients diagnosed with pure seminoma histology in the first tumor. Their mean age was 30.7 years (median 29.3 years; 25–75% quantile was 26.1 and 33.5 years). Primary nonseminomatous TC occurred in 39 patients with the mean age of 22.8 years (median 22.8 years; 25–75% quantile was 20.1 and 25.9 years). The difference was statistically significant ($p < 0.001$).

Similarly, the difference between the mean age of patients with a primary seminoma in unilateral TC (35.8 years) and primary seminoma as the first TC in patients with bilateral disease (30.7 years) was statistically significant ($p = 0.004$).

The same is true for patients with primary nonseminomatous TC. The average age of men with unilateral TC (29.9 year) compared to the average age of men with primary nonseminomatous TC in metachronous disease (22.8 years) was significantly higher ($p < 0.001$).

Out of 24 patients with a pure seminoma in the first TC, the histology was concordant in 17 (70.8%) of cases.

Fifteen (39.5%) patients with a primary nonseminomatous TC presented with the same histology in the opposite side tumor. Presumably, patients with seminoma as the first histology were significantly older than those with a nonseminomatous TC ($p = 0.005$).

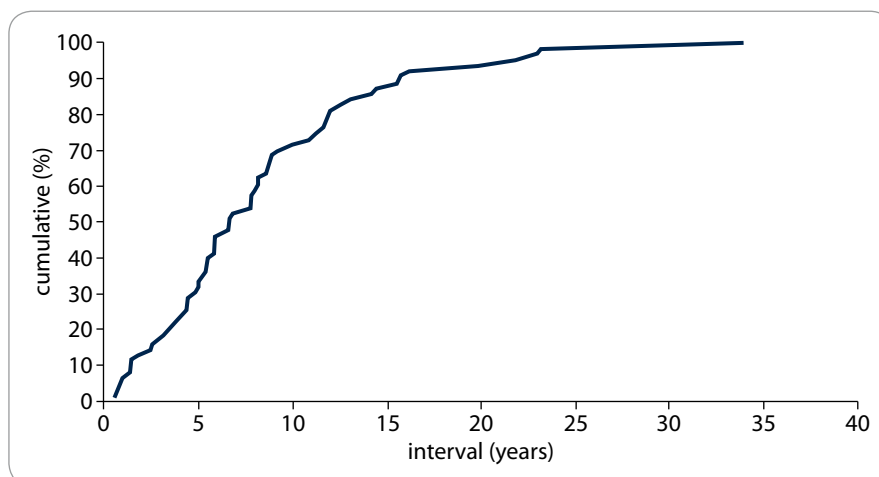
The mean interval between the metachronous tumors was 8.3 years (median 6.7; 25–75% quantile was 4.3 and 11.4 years). Of 63 patients with metachronous tumors, the second TC occurred within five years in 21 patients (33.3%) (Graph 1). In primary seminomas the average time interval between the tumors was 6.9 years (median 6.2 years; 25–75% quantile was 2.9 and 9.0 years) in contrast to 9.2 years in case of consecutive non-seminomas (median 7.8 years; 25–75% quantile was 5.0 and 11.8 years). However, the difference between these intervals was not statistically significant.

Familial occurrence was observed in two non-twin brothers with metachronous bilateral seminoma.

In five (7.4%) patients TC occurred simultaneously (by definition, TC was considered synchronous when the interval between metachronous TC was shorter than three months), with the mean age of patients being 30.1 years (median 26.6 years, 25–75% quantile was 26.0 and 28.7 years). Three of them presented with different histology in each testicle – one patient had an embryonal carcinoma in the left testicle and a seminoma in the right testicle; the second one had a pure seminoma in the left testicle and an embryonal carcinoma with seminoma component in the right testicle, and the third one had a teratoma with a Yolk sac tumor component in the left testicle and a pure seminoma in the opposite side testicle.

Discussion

Several authors have described differences in the incidence of bilateral TC when assorted by their histological features [4,6]. Seminoma was most commonly found in patients aged 31–40 years, whereas younger patients with seminoma (≤ 30 years) had a greater risk of developing a germ cell tumor in the contralateral testis. Nonseminoma-



Graph 1. Time intervals between the first and second tumors in patients with metachronous bilateral germ cell TC.

tous TC was most common in the group of patients aged 21–30 years. There was no significant difference in the incidence of bilateral TC when compared to patients in different age groups [4]. Another study concluded that patients with nonseminomatous histology in the first TC were significantly younger (24 years) than those with initial seminoma (31 years) [6]. Our results confirmed this notion; primary nonseminomatous TC presented in earlier age (22.8 years) than seminomas (30.7 years).

Theodore et al [7] observed that patients with bilateral TC were younger, compared to males with unilateral TC. The mean age at the diagnosis of the first tumor in our patients with a bilateral disease was 25.8 years, and the mean age in patients with unilateral disease at the time of the diagnosis of the first tumor was 31.7 years.

Andreassen et al [6] observed a significantly longer time interval between first and second cancers among patients with initial nonseminomatous TC (6.3 years) compared to patients with a primary seminoma (4.6 years). However, in our study the difference between these two intervals lacked significance (9.2 years vs 6.9 years). Based on analysis of 20 patients with metachronous tumors, Che et al [4] described that in 14 patients (70%) the tumor have recurred within five years, while in the other six patients (30%) developed a second malignancy within 10–15 years in-

terval. In our sample of 63 patients with metachronous TC, 21 men (33.3%) were diagnosed with a subsequent tumor within five years interval, 20 patients (31.2%) after a follow-up period longer than 10 years and five patients (7.9%) after a follow-up of 20 years.

It is widely accepted that synchronous bilateral TC are extremely rare. The most common synchronous TC are seminomas. Their treatment is the same as in a solitary primary germ cell TC. Tumor histology and metastatic disease determine the prognosis of these synchronous malignancies [8]. Concomitant TC developed in 16% of bilateral TC as reported in 29 studies published since the early 80s [9]. In a review by Dieckmann et al [10] out of 151 cases of bilateral synchronous cancer patients, 114 (75.5%) had seminomas in both testicles. Only 19 patients (12.6%) had different histological findings for each tumor. This result has, however, been challenged by several more recent data. Holzbeierlein et al [11] observed that 70% patients with synchronous bilateral TC presented with divergent histologies. Hentrich et al [9] and Klatte et al [12] reported that 54% and 33% patients respectively had discordant histologies. In our study we recorded five cases of simultaneous bilateral TC occurrence (7.4%) with three of them (60%) being histologically distinct.

The need to perform a routine biopsy of the contralateral testis in patients with unilateral TC is a matter of ongoing

discussion [13]. Some European investigators (mainly from Denmark) recommend a biopsy for all TC patients [14], while the others consider the procedure only in high-risk patients [15]. In addition, some authors do not advocate contralateral biopsy at time of diagnosis of primary TC, where by they emphasize the need for a long-term follow-up of these patients [16].

Finally it should be noted that bilaterally orchiectomized TC patients are dependent on a life-long testosterone substitution therapy in order to minimize the long-term adverse effects and risks associated with hypogonadism, such as metabolic syndrome, type 2 diabetes mellitus, cardiovascular disease etc [17].

Conclusions

All patients with unilateral testicular cancer have an increased risk of developing a contralateral testicular malignancy, even decades after the diagnosis. Management of a subsequent tumor should be individualized for each patient according to the histology and cli-

nical stage of the primary tumor, as well as the therapeutic strategy applied initially. The further management should involve a long-term follow-up and life-long testosterone substitution.

References

- Livingstone J. A case of both testicles which terminated favourably by the supprevention of surgery. *Edinburgh M & S J* 1805; 1: 163–165.
- Hamilton JB, Gilbert JB. Studies in malignant tumor of the testis. IV. Bilateral testicular cancer. Incidence, nature, and bearing upon management of the patients with single testicular cancer. *Cancer Res* 1942; 2: 125–129.
- Nery F, Valadares D, Marques F. Metachronous testicular germ cell tumors: the importance of a long-term follow-up. *World J Oncol* 2010; 1(3): 145–147.
- Che M, Tamboli P, Ro JY et al. Bilateral testicular germ cell tumors: twenty-year experience at M. D. Anderson Cancer Center. *Cancer* 2002; 95(6): 1228–1233.
- Park DS, Prow DM, Amato RJ et al. Clinical characteristics of metachronous bilateral testicular tumors in the chemotherapeutic era. *Yonsei Medical J* 1999; 40(2): 137–143.
- Andreassen KE, Grotmol T, Cvancarova MS et al. Risk of metachronous contralateral testicular germ cell tumors: a population-based study of 7,102 Norwegian patients (1953–2007). *Int J Cancer* 2011; 129(12): 2867–2874.
- Theodore Ch, Terrier-Lacombe MJ, Laplanche A et al. Bilateral germ-cell tumours: 22-year experience at the Institut Gustave Roussy. *Br J Cancer* 2004; 90(1): 55–59.
- Hoekstra HJ, Mehta DM, Koops HS. Synchronous bilateral primary germ cell tumors of the testis: a case report and review of the literature. *J Surg Oncol* 1983; 22(1): 59–61.
- Hentrich M, Weber N, Bergsdorf T et al. Management and outcome of bilateral testicular germ cell tumors: Twenty-five year experience in Munich. *Acta Oncol* 2005; 44(6): 529–536.
- Dieckmann KP, Hamm B, Düe W et al. Simultaneous bilateral testicular germ cell tumors with dissimilar histology: case report and review of the literature. *Urol Int* 1988; 43(5): 305–309.
- Holzbeierlein JM, Sogani PC, Sheinfeld J. Histology and clinical outcomes in patients with bilateral testicular germ cell tumors. The Memorial Sloan-Kettering Cancer Center experience 1950 to 2001. *J Urol* 2003; 169(6): 2122–2125.
- Klatte T, de Martino M, Arensmeier K et al. Management and outcome of bilateral testicular germ cell tumors: A 25-year single center experience. *Int J Urol* 2008; 15(9): 821–826.
- Fosså SD, Chen J, Schonfeld SJ et al. Risk of contralateral testicular cancer: a population-based study of 29 515 U.S. men. *J Natl Cancer Inst* 2005; 97(14): 1056–1066.
- Daugaard G, Giwercman A, Skakkebaek NE. Should the other testis be biopsied? *Semin Urol Oncol* 1996; 14(1): 8–12.
- Heidenreich A, Moul JW. Contralateral testicular biopsy procedure in patients with unilateral testis cancer: is it indicated? *Semin Urol Oncol* 2002; 20(4): 234–238.
- Taberner J, Paz-Ares L, Salazar R et al. Incidence of contralateral germ cell testicular tumors in south Europe: report of the experience at 2 Spanish University Hospitals and review of the literature. *J Urol* 2004; 171(1): 164–167.
- Brabrand S, Fosså SD, Cvancarova M et al. Androgen substitution with testosterone undecanoate in survivors of bilateral testicular cancer requires individually-adjusted injection intervals. *BJU Int* 2010; 107(7): 1080–1087.

Informace z České onkologické společnosti

Zápis ze schůze výboru České onkologické společnosti konané dne 15. 10. v Plzni naleznete na www.linkos.cz.